



## The Expression of HER-2 and Ki-67 in Oesophageal Neoplasms

Authors

Meenakshi Somasundaram<sup>1</sup>, Revathi Ramakrishnan<sup>2</sup>

<sup>1</sup>Assistant Professor, Govt Theni Medical College, Theni

<sup>2</sup>Associate Professor, Govt Theni Medical College, Theni

### Abstract

**Introduction:** HER 2 is amplified in up to 25% of patients with oesophageal carcinomas. The presence of this amplification provides a valuable novel therapeutic target for this group of patients. In patients with breast cancer who are HER 2 positive, trastuzumab, [a fully humanized monoclonal antibody which directed at HER 2 which binds the external domain of the receptor and exerts its action] reduced recurrence by about 50 percent. So, esophageal cancer recurrence rate is also expected to reduce with this treatment. None of the ligand belonging to the epidermal growth factor family activates HER 2.

Expression of Ki67 is also an independent prognostic factor. Ki67 are found only in actively proliferating cells. Tumors with deeper invasion and an advance stage showed an overexpression of Ki-67 than those tumors that had a superficial invasion and an early stage. Both HER2 and Ki67 expression is done in this study. This study is to evaluate the expression of HER-2 and KI-67 in oesophageal neoplasms and to analyze the value of expression of HER-2 and Ki-67 in determining the prognosis.

**Materials and Methods:** This is a prospective study undertaken during the period from August 2013 to August 2015. Both the surgical specimens and biopsy material were processed and histopathological diagnosis was made. All the resected specimens were fixed in 10% formalin for 24-48 hours. The immunohistochemical detection of biochemical markers was conducted using monoclonal primary antibody (anti-HER and MIB 1) against HER 2 cytoplasmic antigen and KI-67 nuclear antigen respectively. The super sensitive TM polymer-HRP detection system using biotin polymeric technology was used. In this technique, secondary antibody conjugated to poly-HRP reagent and bound to the primary antibody, is visualized by the DAB. HER 2 and KI67 expressions were interpreted as 0, 1+, 2+, 3+, 4+.

**Observation and Results:** This study is a retrospective one which includes 150 oesophageal biopsies and specimens sent from the medical, surgical and surgical gastroenterology departments, during the period of August 2013 to August 2015.

Out of the 150 samples, 113 were biopsies and 37 were surgical specimens. Of that 10 were negative for malignancy on histopathological examination. The rest of 140 samples were taken for study. In total number of cases of squamous cell carcinomas, 12.5% of the cases are positive for HER2, 25% show equivocal results with HER2 and 62.5% of the cases are negative for HER2. In total number of cases of esophageal adenocarcinoma, 38.46% of cases are positive for HER 2, 30.76% of cases are equivocal, 30.76% of cases are negative for HER 2.

In our study, squamous cell carcinomas (Grade 1-16.66%, Grade 2-66.66%, Grade 3-16.66%) cases with >30% Ki67 expression was seen in 33.33% of cases and they were Grade 2 tumors. In adenocarcinoma (Grade 3-75%, Grade 2-25%), >30% Ki67 expression was seen in % of cases and they were grade 3 tumors.

**Conclusion:** Ki 67 expression proves to be an independent prognostic factor. There is no correlation between the expression of HER2 and Ki 67 expression.

**Key Words:** HER2, Ki 67, oesophageal carcinomas.

## INTRODUCTION

Oesophageal cancer is the 5<sup>th</sup> most common cancer in males and 7<sup>th</sup> most common in females, respectively, and is one of the most aggressive tumors. Male: Female incidence ratio is 3:4.<sup>1,2</sup> According to world cancer statistics, the incidence of oesophageal carcinomas was 481 per lakh population and death occurred in 406 per lakh of affected patients. It has a poor prognosis despite ongoing advances in treatment. Overall, 5 year survival rate is only 9% for esophageal carcinomas. Many patients do not survive one year because of the advanced stage of presentation of this disease. The best promise to improve this poor survival is provided by new targeted agents. Of these, human epidermal growth factor receptor 2 (HER2) is currently in the spotlight.

Human epidermal growth factor receptor gene is a protooncogene and its location is on the short arm of chromosome 7.<sup>3,4,5</sup> This protooncogene encodes for a transmembrane receptor with tyrosine kinase activity (intracellular). This receptor is mainly involved in signal transduction and cause cell growth and differentiation. Four closely related epidermal growth factor receptors include Erb B1, Erb B2 [Her2], Erb B3 and Erb B4. Among that, Her 2 was chosen as a treatment option because of the following reasons:

- HER 2 is amplified in up to 25% of patients with oesophageal carcinomas. The presence of this amplification provides a valuable novel therapeutic target for this group of patients.
- In patients with breast cancer who are HER 2 positive, trastuzumab, [a fully humanized monoclonal antibody which directed at HER 2 which binds the external domain of the receptor and exerts its action] reduced recurrence by about 50 percent. So, esophageal cancer recurrence rate is also expected to reduce with this treatment.
- None of the ligand belonging to the epidermal growth factor family activates HER 2.

To prove that, TOGA trial was undertaken which revealed a combination of antibody with chemotherapy significantly improved the response rate and overall survival rate without additional toxicity. Median survival of 11.1 months with chemotherapy, significantly increased to 13.8 months with the addition of trastuzumab.

Patients with HER2-expressing tumors who were in advanced stages (could not be removed surgically) were treated with chemotherapy and trastuzumab or with chemotherapy alone in another study. Patients who received trastuzumab therapy responded to treatment and lived about 2.4 months longer than who were treated with chemotherapy alone<sup>5</sup>. Following these, trastuzumab was approved in 2010 for treatment of patients with esophageal cancer with HER 2 overexpression.

Expression of Ki67 is also an independent prognostic factor. Ki67 are found only in actively proliferating cells.<sup>6,7</sup> Tumors with deeper invasion and an advance stage showed an overexpression of Ki-67 than those tumors that had a superficial invasion and an early stage. Both HER2 and Ki67 expression is done in this study.

This study is

- To evaluate the expression of HER-2 and KI-67 in oesophageal neoplasms.
- To analyze the value of expression of HER-2 and Ki-67 in determining the prognosis

## MATERIALS AND METHODS

This is a prospective study undertaken in the department of pathology, Madurai Medical College, Madurai during the period from August 2013 to August 2015. During this study period, both the surgical specimens and biopsy material were processed and histopathological diagnosis was made in the department of pathology, Madurai Medical College, Madurai. All the resected specimens were fixed in 10% formalin for 24-48 hours. We have received a total of 37 esophagectomy specimens and 113 esophageal biopsies. Out of 37 resected specimens and optimize

therapeutic decisions and improve the survival of affected patients. esophageal specimens, 24 are squamous cell carcinomas and 13 are adenocarcinomas. Out of 113 esophageal biopsies received, 94 were diagnosed as neoplastic.

The immunohistochemical detection of biochemical markers was conducted using monoclonal primary antibody (anti-HER and MIB 1) against HER 2 cytoplasmic antigen and KI-67 nuclear antigen respectively. The super sensitive TM polymer-HRP detection system using biotin polymeric technology was used. In this technique, secondary antibody conjugated to poly-HRP reagent and bound to the primary antibody, is visualized by the DAB.

### **IHC PROCEDURE**

1. Dewax the section in xylene (15 minutes each, 2 changes) and then in decreasing grades of alcohol then finally bring the sections to running tap water followed by distilled water.
2. Antigen retrieval using Tris Buffer Saline by the pressure cooker method
3. Cool to room temperature in running tap water for 15 minutes
4. Wash in Tris Buffer Saline -2 Changes for 5 minutes
5. Drain and cover the sections with peroxidase block (endogenous peroxidase blocking agent) for 15 minutes
6. Wash in Tris Buffer Saline-2 changes for 5 minutes each
7. Drain and cover the tissue sections with power block for 15 minutes
8. Drain and blot the excess power block
9. Cover the sections with the respective primary antibody for 90 minutes
10. Wash in Tris Buffer Saline-2 changes for 5 minutes each
11. Drain and cover the sections with super enhancer for 30 minutes
12. Wash in Tris Buffer Saline-2 changes for 5 minutes each
13. Drain and cover the tissues with secondary antibody (HRP-horse radish peroxidase)

14. Wash in Tris Buffer Saline -2 changes for 15 minutes each

15. Drain and cover the tissue sections with DAB (Diamino Benzidine) substrate buffer for 5 -10 minutes.

### **FOR BIOPSIES**

#### **HER 2 INTERPRETATION.**

0 (negative): No staining is observed or membranous staining is observed in less than less than 5 the tumor cells.

1+ (negative): A faint/barely perceptible complete/basolateral/lateral staining in cohesive cluster of at least 5 tumor cells (visible only at 40x) irrespective of tumor volume.

2+ (equivocal): A faint/barely perceptible complete/basolateral/lateral staining in cohesive cluster of at least 5 tumor cells (visible only at 10-20x) irrespective of tumor volume.

3+ (positive): A strong membrane staining in cohesive clusters of at least 5 tumor cells (visible at 5x) irrespective of tumor volume

- Cases that are negative by IHC (0 & 1+) are reported out as “negative”, and strongly positive cases (3+) are reported out as “positive”.

Weakly positive (2+) or equivocal IHC should be further analyzed for HER 2 gene amplification by

### **FISH (CISH).**

#### **FOR SPECIMENS**

#### **HER 2 INTERPRETATION.**

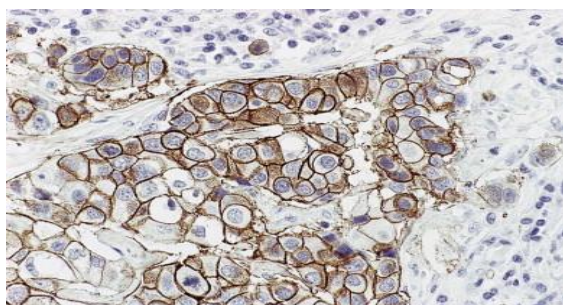
0 (negative): No staining is observed or membranous staining is observed in less than 10% of the tumor cells.

1+ (negative): A faint/barely perceptible staining is detected in more than 10% of the tumor cells. The cells are stained in part of their membrane.

2+ (equivocal): A weak to moderate complete membrane staining is observed in more than 10% of the tumor cells. HER2 FISH is being performed and will be subsequently reported.

3+ (positive): A strong complete membrane staining is observed in more than 30% of the tumor cells.

Her 2/neu  
3+



### KI 67

Ki-67 (MIB1) is a monoclonal antigen that interacts with human nuclear antigen Ki-67, which is present in proliferating cells. In normal esophagus, KI 67 expression is limited to basal and parabasal layers only. The conventional 3-4 micrometer sections were cut from paraffin blocks and the Immuno histochemical staining procedure was performed with Murine monoclonal antibody-MIB1. Labeling index was measured as percentage of MIB-1 Positive cells in 1000 tumor cells that are randomly selected. Only strong brown color nuclear staining is considered positive. Weak nuclear or cytoplasmic staining are considered as negative and excluded in count. The proliferative index was categorized into two based on the percentage of strong staining of nuclei as <30% and >30%.

### OBSERVATION AND RESULTS

This study is a retrospective one which includes 150 oesophageal biopsies and specimens sent from the medical, surgical and surgical gastroenterology departments at Madurai medical college, to the Department of Pathology, during the period of August 2013 to August 2015.

Out of the 150 samples, 113 were biopsies and 37 were surgical specimens. Of that 10 were negative for malignancy on histopathological examination. The rest of 140 samples were taken for study.

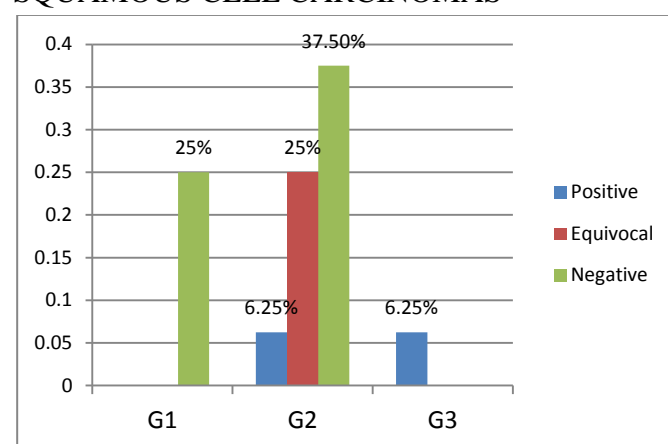
In total number of cases of squamous cell carcinomas, 12.5% of the cases are positive for HER2, 25% show equivocal results with HER2

and 62.5% of the cases are negative for HER2 as depicted in table 1.

**TABLE 1** HER2 EXPRESSION IN DIFFERENT GRADES OF OESOPHAGEAL SQUAMOUS CELL CARCINOMAS

Grade	Positive	Equivocal	Negative
G1	0	0	25%
G2	6.25%	25%	37.5%
G3	6.25%	0	0
Total	12.5%	25%	62.5%

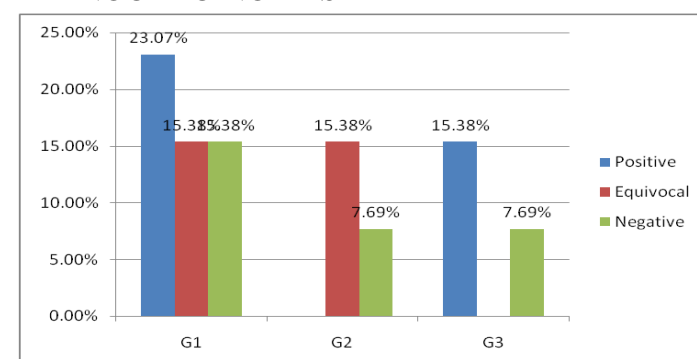
**CHART 1:** HER2 EXPRESSION IN DIFFERENT GRADES OF OESOPHAGEAL SQUAMOUS CELL CARCINOMAS



**TABLE 2:** HER2 EXPRESSION IN DIFFERENT GRADES OF OESOPHAGEAL ADENOCARCINOMAS

Grade	Positive	Equivocal	Negative
G1	23.07%	15.38%	15.38%
G2	0	15.38%	7.69%
G3	15.38%	0	7.69%
TOTAL	38.46%	30.76%	30.76%

**CHART 2:** HER2 EXPRESSION IN DIFFERENT GRADES OF OESOPHAGEAL ADENOCARCINOMAS





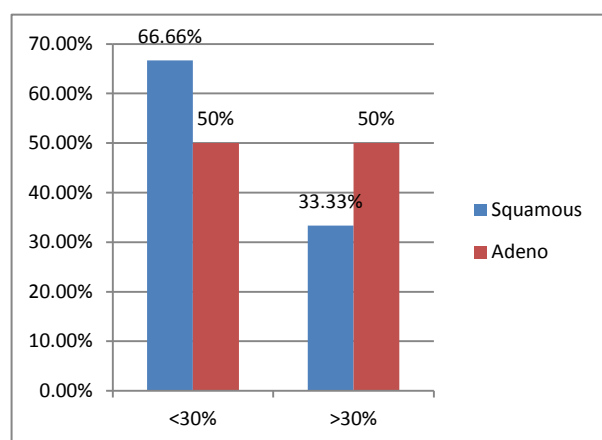
In total number of cases of esophageal adenocarcinoma, 38.46% of cases are positive for HER 2, 30.76% of cases are equivocal, 30.76% of cases are negative for HER 2 .

**TABLE 3:** KI67 EXPRESSION IN OESOPHAGEAL SQUAMOUS CELL CARCINOMAS AND ADENO CARCINOMAS

Ki67	<30%	>30%	TOTAL
Squamous	66.66%	33.33%	100%
Adeno	50%	50%	100%

In our study, squamous cell carcinomas (Grade 1-16.66%, Grade 2-66.66%, Grade3-16.66%) cases with >30% Ki67 expression was seen in 33.33% of cases and they were Grade 2 tumors. In adenocarcinoma (Grade3-75%, Grade 2-25%), >30% Ki67 expression was seen in % of cases and they were grade 3 tumors.

**CHART 3:** KI67 EXPRESSION IN OESOPHAGEAL SQUAMOUS CELL CARCINOMAS AND ADENO CARCINOMAS



## DISCUSSION

HER2/neu EXPRESSION IN OESOPHAGEAL CARCINOMA HER(3+) EXPRESSION OF SCC AND ADENO CARCINOMA

**TABLE: 4**

	SCC(HER 3+)	ADENO CA(HER 3+)
Dreilich M et al	13%	30%
Present study	12.5%	38.5%

In this study HER2 positive, more in adenocarcinoma (38.46%) than squamous cell carcinoma (12.5%) of the Oesophagus. This is in correlation with the study by Dreilich M et al.<sup>8,9,10</sup>

**TABLE:5** INCIDENCE OF LEVELS OF HER2 EXPRESSION IN ESOPHAGEALA-DENO CARCINOMA [EAC]

Study	3+	2+	1+	0
Harry H.Yoon et al (EAC)	13%	24 %	22%	40%
Hazem Al. Momani et al (EAC)	18%	16 %	38%	28%
Present Study	38.46%	30.76%	15.38%	15.38%

In this study, the Ki67 proliferative index was strong and increased in carcinomas, which is similar to other studies<sup>11,12,13,14</sup> on Ki67, and percentage of positive tumor cells counted were high in high grade carcinomas when compared with more differentiated carcinomas.

## TREATEMENT STRATEGIES

Antibody based therapy with trastuzumab is used clinically for targeting HER 2 positive breast cancers.HER2 overexpression was reported in esophageal cancers also.<sup>15,16,17</sup> Esophageal cancer patients who express HER-2 –overexpression in primary tumors are candidates for trastuzumab therapy<sup>18,19,20</sup>

ToGA trial was done to study the safety and efficacy of trastuzumab in HER2 positive advanced gastroesophageal carcinoma cases.<sup>21,22,23,24</sup> Later many other drugs like Gefitinib, Erlotinib and newer Lapatinib have been developed against HER2.<sup>25,26,27</sup>

HER 2 over expression in esophageal squamous cell carcinoma is rare.<sup>28,29,30</sup> HER 2 is overexpressed in around 15% of adenocarcinoma of the esophagus. Those patients might benefit from a HER 2 targeted therapy.

## SUMMARY AND CONCLUSSION

- HER 2 expression was positive in 23.33% of the lesions including Squamous cell carcinomas (12.5%) and Adenocarcinomas (38.46%).
- HER 2 overexpression are seen in higher grades of carcinomas and maximum number of cases with HER2 expression is seen in esophageal adenocarcinomas (out

of 23.33% HER2 positive cases, 16.66% cases are esophageal adenocarcinomas).

- HER 2 expression in more number of esophageal adenocarcinomas when compared with squamous cell carcinomas.
- HER 2 expression is an important prognostic factor after nodal metastasis.
- If the esophageal adenocarcinoma is HER2 positive, the patient is benefited by targeted therapy (trastuzumab). This targeted therapy definitely improves the patient survival.
- Ki 67 expression is high (>30%) in 40% of the cases and low (<30%) in 60% of the cases.
- Ki 67 expression proves to be an independent prognostic factor. There is no correlation between the expression of HER2 and Ki 67 expression

## REFERENCES

1. Akamatsu M, Matsumoto T, Oka K, Yamasaki S, Sonoue H, Kajiyama Y, et al. c-erbB-2 oncoprotein expression related to chemoradioresistance in esophageal squamous cell carcinoma. *Int J Radiat Oncol Biol Phys.* 2003;57(5):1323–1327. doi: 10.1016/S0360-3016(03)00782J
2. Anderson KS, LaBaer J. The sentinel within: exploiting the immune system for cancer biomarkers. *J Proteome Res.* 2005;4:1123–1133. doi: 10.1021/pr0500814.
3. Bagaria B, Sood S, Sharma R, Lalwani S. Comparative study of CEA and CA19-9 in esophageal, gastric and colon cancers individually and in combination (ROC curve analysis) *Cancer Biol Med.* 2013;10(3):148–157.
4. Berry MF. Esophageal cancer: staging system and guidelines for staging and treatment. *J Thorac Dis.* 2014;6(3):289.
5. Bird-Lieberman EL, Dunn JM, Coleman HG, Lao-Sirieix P, Oukrif D, Moore CE, et al. Population-based study reveals new risk-stratification biomarker panel for Barrett's esophagus. *Gastroenterology.* 2012;143(4):927–935 e3. doi: 10.1053/j.gastro.2012.06.041.
6. Cerfolio RJ, Bryant AS, Ohja B, Bartolucci AA, Eloubeidi MA. The accuracy of endoscopic ultrasonography with fine-needle aspiration, integrated positron emission tomography with computed tomography, and computed tomography in restaging patients with esophageal cancer after neoadjuvant chemoradiotherapy. *J Thorac Cardiovasc Surg.* 2005;129:1232–1241. doi: 10.1016/j.jtcvs.2004.12.042
7. Chan DS, Twine CP, Lewis WG. Systematic review and meta-analysis of the influence of HER2 expression and amplification in operable oesophageal cancer. *J Gastrointest Surg.* 2012;16(10):1821–1829. doi: 10.1007/s11605-012-1979-2.
8. DiMaio MA, Kwok S, Montgomery KD, Lowe AW, Pai RK. Immunohistochemical panel for distinguishing esophageal adenocarcinoma from squamous cell carcinoma: a combination of p63, cytokeratin 5/6, MUC5AC, and anterior gradient homolog 2 allows optimal subtyping. *Hum Pathol.* 2012;43(11):1799–1807. doi: 10.1016/j.humpath.2012.03.019.
9. Dong J, Zeng BH, Xu LH, Wang JY, Li MZ, Zeng MS, et al. Anti-CDC25B autoantibody predicts poor prognosis in patients with advanced esophageal squamous cell carcinoma. *J Transl Med.* 2010;8:81. doi: 10.1186/1479-5876-8-81.
10. Dreilich M, Wanders A, Brattstrom D, Bergstrom S, Hesselius P, Wagenius G, et al. HER-2 overexpression (3+) in patients with squamous cell esophageal carcinoma correlates with poorer survival. *Dis*

- Esophagus. 2006;19(4):224–231. doi: 10.1111/j.1442-2050.2006.00570.
11. Duong C, Greenawalt DM, Kowalczyk A, Ciavarella ML, Raskutti G, Murray WK, et al. Pretreatment gene expression profiles can be used to predict response to neoadjuvant chemoradiotherapy in esophageal cancer. *Ann Surg Oncol*. 2007;14(12):3602–3609. doi: 10.1245/s10434-007-9550-1.
  12. Enzinger PC, Mayer RJ. Esophageal cancer. *N Engl J Med*. 2003;349:2241–2252. doi: 10.1056/NEJMra035010.
  13. Finn OJ. Immune response as a biomarker for cancer detection and a lot more. *N Engl J Med*. 2005;353:1288–1290. doi: 10.1056/NEJMe058157.
  14. Fitzgerald RC, di Pietro M, Ragnath K, Ang Y, Kang JY, Watson P, et al. British Society of Gastroenterology guidelines on the diagnosis and management of Barrett's oesophagus. *Gut*. 2014;63(1):7–42. doi: 10.1136/gutjnl-2013-305372.
  15. Glickman JN, Yang A, Shahsafaei A, McKeon F, Odze RD. Expression of p53-related protein p63 in the gastrointestinal tract and in esophageal metaplastic and neoplastic disorders. *Hum Pathol*. 2001;32:1157–1165. doi: 10.1053/hupa.2001.28951.
  16. Hiyoshi Y, Kamohara H, Karashima R, Sato N, Imamura Y, Nagai Y, et al. MicroRNA-21 regulates the proliferation and invasion in esophageal squamous cell carcinoma. *Clin Cancer Res*. 2009;15(6):1915–1922. doi: 10.1158/1078-0432.CCR-08-2545.
  17. Huang YW, Liu JC, Deatherage DE, Luo J, Mutch DG, Goodfellow PJ, et al. Epigenetic repression of microRNA-129-2 leads to overexpression of SOX4 oncogene in endometrial cancer. *Cancer Res*. 2009;69(23):9038–9046. doi: 10.1158/0008-5472.CAN-09-1499.
  18. Jemal A, Bray F, Center MM, Ferlay J, Ward E, Forman D. Global cancer statistics. *CA Cancer J Clin*. 2011;61:69–90. doi: 10.3322/caac.20107.
  19. Kan T, Sato F, Ito T, Matsumura N, David S, Cheng Y, et al. The miR-106b-25 polycistron, activated by genomic amplification, functions as an oncogene by suppressing p21 and Bim. *Gastroenterology*. 2009;136(5):1689–1700. doi: 10.1053/j.gastro.2009.02.002.
  20. Kang M, Li Y, Liu W, Wang R, Tang A, Hao H, et al. miR-129-2 suppresses proliferation and migration of esophageal carcinoma cells through downregulation of SOX4 expression. *Int J Mol Med*. 2013;32(1):51–58.
  21. Kaye PV, Haider SA, Ilyas M, James PD, Soomro I, Faisal W, et al. Barrett's dysplasia and the Vienna classification: reproducibility, prediction of progression and impact of consensus reporting and p53 immunohistochemistry. *Histopathology*. 2009;54(6):699–712. doi: 10.1111/j.1365-2559.2009.03288.
  22. Kilic A, Schuchert MJ, Luketich JD, Landreneau RJ, Lokshin AE, Bigbee WL, et al. Use of novel autoantibody and cancer-related protein arrays for the detection of esophageal adenocarcinoma in serum. *J Thorac Cardiovasc Surg*. 2008;136:199–204. doi: 10.1016/j.jtcvs.2008.01.012.
  23. Kumar A, Chatopadhyay T, Raziuddin M, Ralhan R. Discovery of deregulation of zinc homeostasis and its associated genes in esophageal squamous cell carcinoma using cDNA microarray. *Int J Cancer*. 2007;120:230–242. doi: 10.1002/ijc.22246.
  24. Lesnikova I, Lidang M, Hamilton-Dutoit S, Koch J. HER2/neu (c-erbB-2) gene amplification and protein expression are rare in uterine cervical neoplasia: a tissue microarray study of 814 archival

- specimens. APMIS. 2009;117(10):737–745. doi: 10.1111/j.1600-0463.2009.02531.
25. Luthra R, Singh RR, Luthra MG, Li YX, Hannah C, Romans AM, et al. MicroRNA-196a targets annexin A1: a microRNA-mediated mechanism of annexin A1 downregulation in cancers. *Oncogene*. 2008;27(52):6667–6678. doi: 10.1038/onc.2008.256.
26. Mathe EA, Nguyen GH, Bowman ED, Zhao Y, Budhu A, Schetter AJ, et al. MicroRNA expression in squamous cell carcinoma and adenocarcinoma of the esophagus: associations with survival. *Clin Cancer Res*. 2009;15(19):6192–6200. doi: 10.1158/1078-0432.CCR-09-1467.
27. Matsushima K, Isomoto H, Yamaguchi N, Inoue N, Machida H, Nakayama T, et al. MiRNA-205 modulates cellular invasion and migration via regulating zinc finger E-box binding homeobox 2 expression in esophageal squamous cell carcinoma cells. *J Transl Med*. 2011;9:30. doi: 10.1186/1479-5876-9-30.
28. Motoori M, Takemasa I, Yamasaki M, Komori T, Takeno A, Miyata H, et al. Prediction of the response to chemotherapy in advanced esophageal cancer by gene expression profiling of biopsy samples. *Int J Oncol*. 2010;37(5):1113–1120.
29. Ohta M, Mimori K, Fukuyoshi Y, Kita Y, Motoyama K, Yamashita K, et al. Clinical significance of the reduced expression of G protein gamma 7 (GNG7) in oesophageal cancer. *Br J Cancer*. 2008;98(2):410–417. doi: 10.1038/sj.bjc.6604124.
30. Pacha A, Rygiel AM, Westra W, Dijkgraaf MG, Rosmolen W, Visser M, et al. Su1181 A diagnostic DNA fish biomarker assay identifies HGD or EAC in Barrett esophagus. *Elsevier Gastroenterol*. 2012;142(5):S-445. doi: 10.1016/S0016-5085(12)61675-8