



Case Report

Anaesthetic Management of Pregnant Patient for LSCS with Intracranial Space Occupying Lesion

Authors

**Radhika Chendragiri¹, M. H. Nagrale², B. Kishan Rao³, S. Kiran Kumar³,
A. Srikanth³, K. Swathi³**

Department of Anaesthesia, Mamata Medical College, Khammam, Telangana, India

Corresponding Author

Radhika ChendragiriH.NO. 3-9-39/3, Konduri Complex, Near Santhoshimata Temple, Jammikunta, Karimnagar District,
Telangana-505122, IndiaEmail: radhikadhanraj123@gmail.com**Abstract**

Intracranial space occupying lesion [SOL] during pregnancy presents several challenges to the neurosurgeons, obstetricians and anaesthesiologists in not only establishing the diagnosis, but also in the perioperative management as it requires a careful plan to balance both maternal and foetal well-being. It requires modification of neuroanaesthetic and obstetric practices which often have competing clinical goals to achieve the optimal safety of both mother and foetus. Intracranial calcified granuloma should be considered in the differential diagnosis of intracranial SOL in pregnant women with signs and symptoms of raised intracranial pressure with or without neurological deficits, especially when they are from high incidence areas.

Keywords: *Neuro-anaesthesia, pregnancy, calcified granuloma, Cesarean section.*

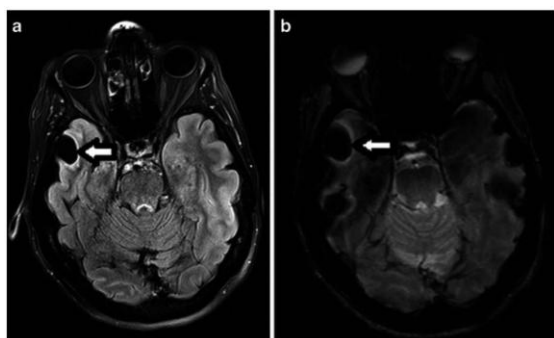
Introduction

Anaesthetic management of a pregnant patient with an intracranial space occupying lesion (SOL) requires modification of neuroanaesthetic and obstetric practices, which have competing clinical goals to achieve the optimal safety of both mother and foetus.^[1] Maternal alterations during pregnancy may complicate the anaesthetic management and increase monitoring requirements for safety of both mother and foetus.^{[2],[3]}

Case Report

We report a case of 22-year-old woman, gravida2 para1, 39 weeks pregnant, weighing 60kgs, presented with H/o one episode of seizure, tonic-clonic type, H/o loss of consciousness, tongue bite, frothing mouth and post-ictal confusion one week back. H/o headache present. Similar complaints were present at 5th month of gestational age. No H/o fever. H/o abdomen pain on and off associated with tightening. The neurosurgical team made a clinical diagnosis of right temporal intracranial SOL. Magnetic

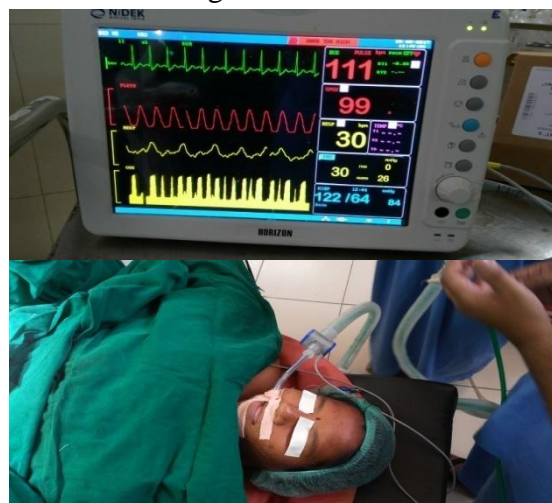
resonance imaging (MRI) brain revealed calcified granuloma in right temporal lobe. Patient was using leveteracetam 500mg BD since 1wk. Patient was examined by the obstetric team and fetal well-being was determined. Pre-anaesthetic checkup was done. Past history- previous LSCS under subarachnoid block. No significant personal, family and medical history. General examination-wt-60kgs, moderate built, BMI-22, Airway examination- mallampati grade 2. No pallor, icterus, clubbing, koilonychia and lymphadenopathy. Vitals: PR-88/min, R.R-14/min, BP-120/80, TEMP-normal. Investigations: Hb-11gm%, major surgical profile-normal. ECG-NAD, MRI brain-Right temporal calcified granuloma.



Anaesthetic Management

Patient was pre-medicated with Inj. ranitidine and Inj. Metoclopramide as prophylaxis against aspiration. Inj. Leveteracetam 1gm iv infused. In the operating theatre, initial monitoring consisted of electrocardiogram, pulse oximeter, non-invasive blood pressure and capnography. Two large bore [18G] peripheral intravenous (IV) cannula were secured. Patient was slightly tilted to the left and a wedge placed under the right buttock to avoid aorto-caval compression. After pre-oxygenation, modified rapid sequence induction and intubation was performed using thiopentone 5 mg/kg and rocuronium 1.5 mg/kg. Inj. Loxicard 1.5mg/kg was given. cuffed endotracheal tube size 7 was used. Anaesthesia was maintained with 10 lit of oxygen initially. Baby was extracted. Syntocinon 10 IU infusion started. After that anaesthesia was maintained with isoflurane 0.7 MAC in oxygen and air, vecuronium, fentanyl

2µg/kg. Additional monitoring included urinary catheter, oesophageal temperature probe and arterial blood pressure (BP). Patient was haemodynamically stable throughout the procedure, with systolic BP between 100 and 120 mm Hg, heart rate 60-80 beats/min, R.R 16-18/min, Spo2 (98-100%), ETCO2 (28-34 mm Hg) and body temperature (36-37°C) were maintained. 700 ml of crystalloids was infused. Estimated blood loss was 400 ml and urine output was maintained at >1 ml/kg/hr. Intra-operative arterial blood gas analysis showed values were: PH- 7.42, pco2 32.6 mm Hg, po2 239.9 mm Hg, HCO3 23.0 m mol/l, O2 Sat 99.6%. At the end of the procedure, neuromuscular blockade was reversed with neostigmine 2.5mg and glycopyrrolate 0.5mg. For smooth extubation loxicard 1ml was given. Patient was extubated fully awake, with no new neurological deficits in the operating theatre and shifted to intensive care unit for observation and referred to neurosurgery. Fetal outcome was good.



Discussion

The anaesthetic goals in a patient with intracerebral space occupying lesion (SOL) should be combined to that of principles of obstetrical anaesthesia to ensure a favourable maternal and fetal outcome. The anaesthetic technique chosen should prevent aspiration, avoid fluctuations in intracranial pressure, maintain stable haemodynamics and provide a sufficient depth of anaesthesia and postoperative analgesia.

The risks of increased intracranial pressure and full stomach must be weighed while planning general anaesthesia for caesarean section. One must avoid drugs which lower seizure threshold such as ketamine, enflurane and meperidine.

We did not consider subarachnoid block for our patient as there is high risk of lumbar puncture induced herniation especially with temporal mass lesion associated with shift and brain stem compression. Other problem associated is risk of hypotension which can decrease cerebral perfusion or aggravate brain shifts.

An alternative could have been epidural block. However, it also carries the risk of accidental dural puncture which can lead to acute neurological deterioration.⁴ Further, onset of block takes time and is not appropriate in the setting of emergency situation like fetal distress as seen in our patient.

Caudal anaesthesia has been used to reduce the risk of dural puncture. However, it provides inadequate analgesia in 10-20% of patients and also requires larger doses of local anaesthetic, which results in greater risk of maternal toxicity.⁵ Women with active epilepsy may have an increased risk of convulsion during labour if they receive extra dural analgesia and use of this technique in a patient with intracranial SOL may carry the same risk.⁶

Conclusion

Management of obstetric patients with intracranial space occupying lesions is complex, requiring knowledge of the physiological effects of pregnancy on tumour size and labour on intracranial pressure. General anaesthesia combined with multimodal balanced analgesia is associated with a favorable outcome.

References

1. Wang LP, Paech MJ. Neuroanaesthesia for the pregnant woman. *Anesth Analg* 2008; 107:193-200.
2. Cok OY, Akin S, Aribogan A, Acil M, Erdogan B, Bagis T. Anesthetic

management of 29 week pregnant patient undergoing craniotomy for pituitary macroadenoma - A case report. *Middle East J Anaesthesiol* 2010; 20:593-6.

3. Van De Velde M, De Buck F. Anesthesia for non-obstetric surgery in the pregnant patient. *Minerva Anesthesiol* 2007;73:235-40
4. Richards PG, Towu-Aghantse E. Dangers of lumbar puncture. *BMJ* 1986; 292: 605-6. [PUBMED]
5. Russel PH, Coakley CS. Re-evaluation of continuous caudal anaesthesia for obstetrics. *Surgery, Gynaecology and Obstetrics* 1964; 119: 531-4.
6. Anderson S. Management of epilepsy. *Lancet* 1990; 336: 1127.