



## Functional Outcome of Locking Compression plating for Osteoporotic Periarticular Fractures

Authors

**Dr S.Alfred Sathiya Sekar<sup>1</sup>, Dr Noorul Ameen<sup>2</sup>, Dr A.Mohamed Zubair<sup>3</sup>, Dr M.Akela<sup>4</sup>**

<sup>1</sup>Assistant Professor in Orthopedic Surgery, Kanyakumari Govt Medical College, Asaripallam, Nagercoil

<sup>2</sup>Junior Resident, Sree Balaji Medical College and Hospital, Chrompet, Chennai, Bharath University

<sup>3</sup>Assistant Professor in Orthopedic Surgery, Kanyakumari Govt Medical College, Asaripallam, Nagercoil

<sup>4</sup>Intern at Kanyakumari Government Medical College, Asaripallam, Nagercoil

### Abstract

**Background:** The aim of the study is to analyse the short term results in terms of union and functional outcome for osteoporotic periarticular fractures using locking compression plate in the department of Orthopaedics, KGMCH, Asaripallam over a period of one year from March 2016-March 2017.

**Materials and Methods:** This is a prospective study of 22 cases of osteoporotic periarticular fractures treated by locking compression plate.

**Results:** The osteoporotic periarticular fractures occurs more commonly among females in Distal femur. Locking compression plating results in solid union with good stability and also prevents implant failure as the screws are firmly positioned.

**Conclusion:** The locking compression plates provide better fixation in osteoporotic fractures. As these plates have limited contact with bones there is minimal disruption of sub-periosteal blood supply to the fracture ends and this helps in good union. Secondary angular deformities are prevented as the locked screw prevents further tightening.

### Introduction

Periarticular osteoporotic fractures of long bones are becoming common now. In elderly patients with osteoporosis it occurs usually due to low velocity injury like fall by slipping/tripping during walking. Because of the proximity of periarticular fractures to the corresponding joints, regaining full motion and function may be difficult and treatment may be complicated by coexisting osteoporosis.

Conservative treatment results in joint stiffness, malunion and nonunion and so surgical intervention is necessary. Early surgical

stabilization can facilitate care of soft tissue, permits early mobility and reduces the complexity of nursing care.

### Inclusion criteria

1. Age more than 50 years.
2. Osteoporotic bones either disuse, nutritional deficiency or physiological ageing.
3. Fractures occurring near joints in major bones.
4. Osteoporotic non unions.

### Exclusion criteria

1. Patients with tumor pathology.

2. Severe comminution with extension into articular surface.
3. Undisplaced fracture patterns needing only conservative management.
4. Patients not willing for internal fixation.

### Special surgical considerations

Reduced bone mass, increased bone brittleness, and structural changes such as medullary expansion must be taken into account in the osteoporotic patients when deciding the type of surgical method to be used.

Immobilization in casts has the disadvantage of immobilizing the joint adjacent to the fracture often leading to joint stiffness. The main problem in osteoporotic fracture treatment is fixation of the device to the bone as bone failure is much more common than implant breakage. Problem with external fixator is loosening of the device which is often followed by pin infection and local bone resorption sometimes leading to secondary fracture at pin site.

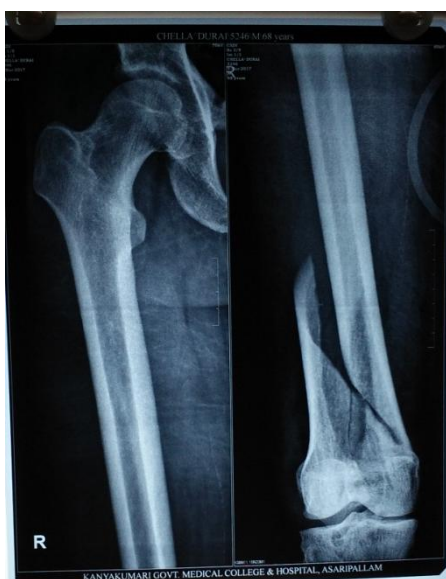With Conventional Bone Plating, fracture reduction is lost from axial loads causing excessive shear forces on the construct that are greater than the frictional loads between the bone-

plate-screw construct. The cortical screws can toggle which leads to screw loosening and loss of plate-bone fixation.

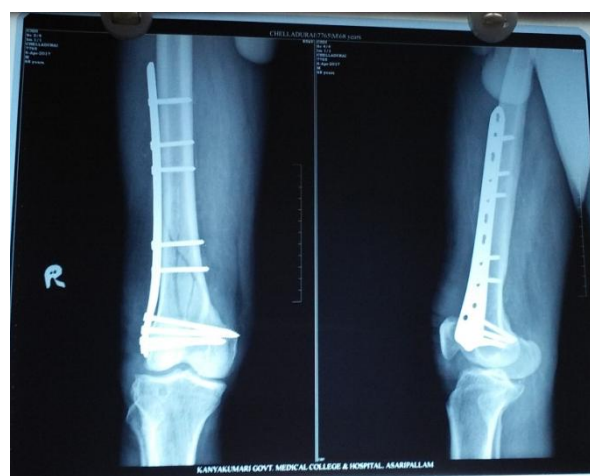In LCP the screw is locked into the plate, the fixed angle converts shear stress into compressive stress at the screw-bone interface. Locking screws are designed with smaller threads because they are not used to generate compression between the plate and the bone. They have a larger core diameter that ensures greater bending and shear strength. Locking the screw to a plate may be an advantage when the distal fragment is relatively short. Using a locked construct will allow the creation of a fixed angle device, it will allow the plate to be used to facilitate the reduction.

The undersurface of this plate has small undulations so that the plate contacts the bone at intermittent alternating points, this allows preservation of periosteal circulation. Locking plates with threaded screw holes in the plates create angular stability between the screws and the plate. LCP provides 3 times greater stability than a standard lateral condylar buttress plate and about 2.5 times greater stability than a 95-degree condylar plate in axial loading.

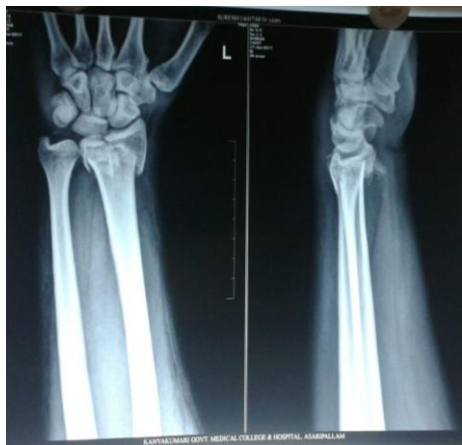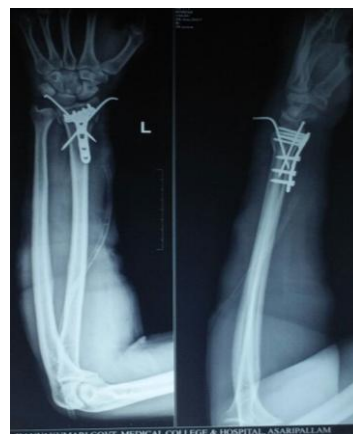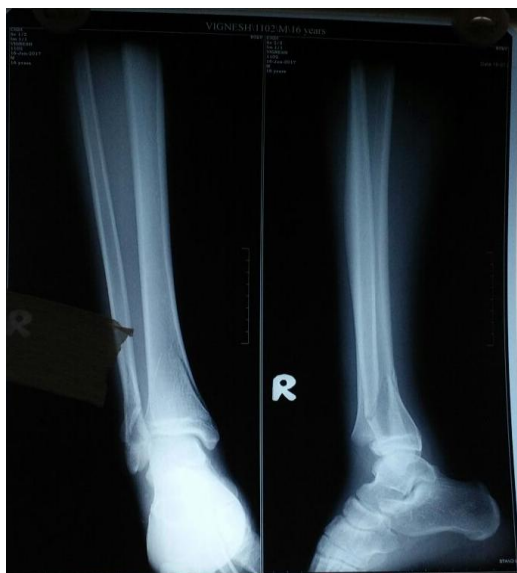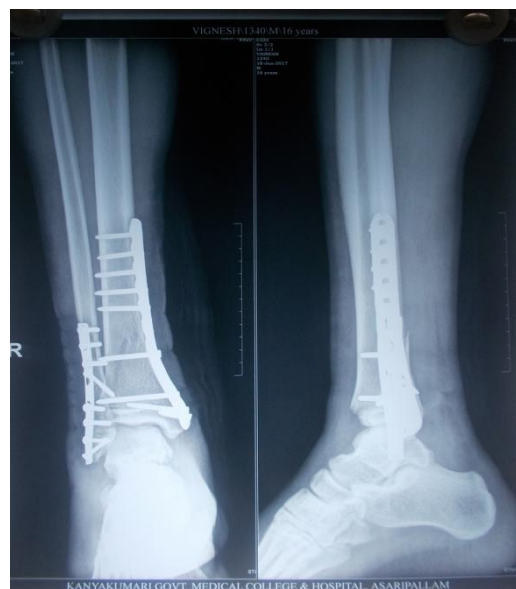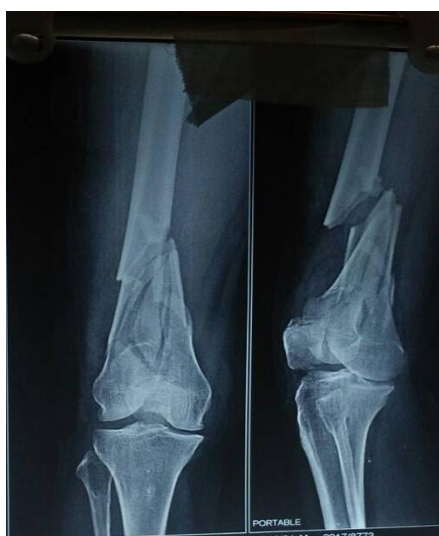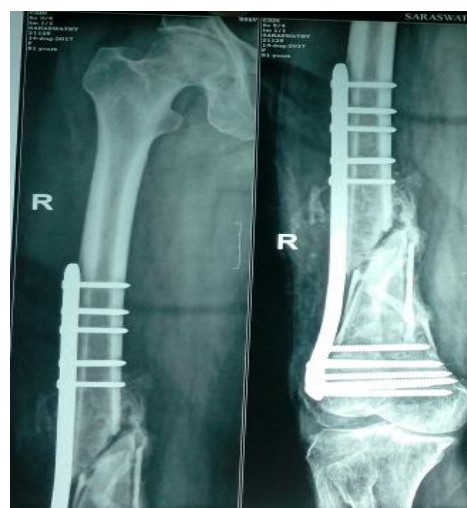### Case 1

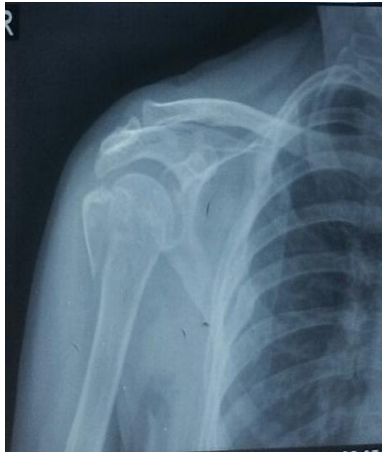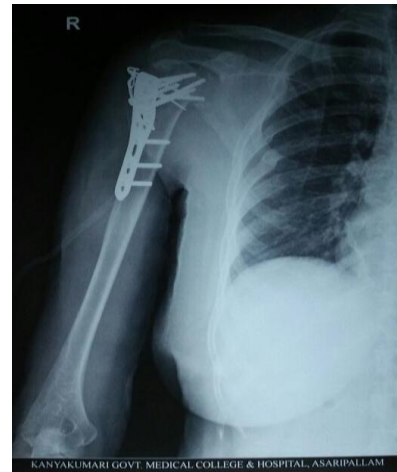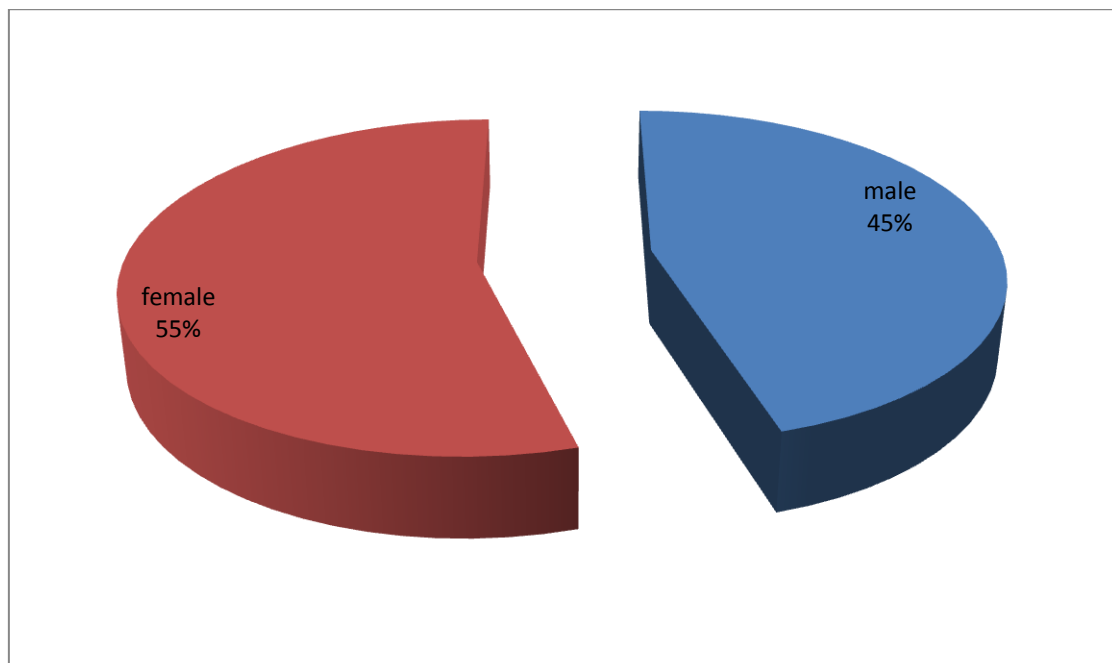


Pre-operative



post operative

**Case 2****Preoperative****Postoperative****Case 3****Pre Operative****Post Operative****Case 4****Pre Operative****Post Operative**

**Case 5****Pre operative****post operative****Sex Incidence****Site Incidence**

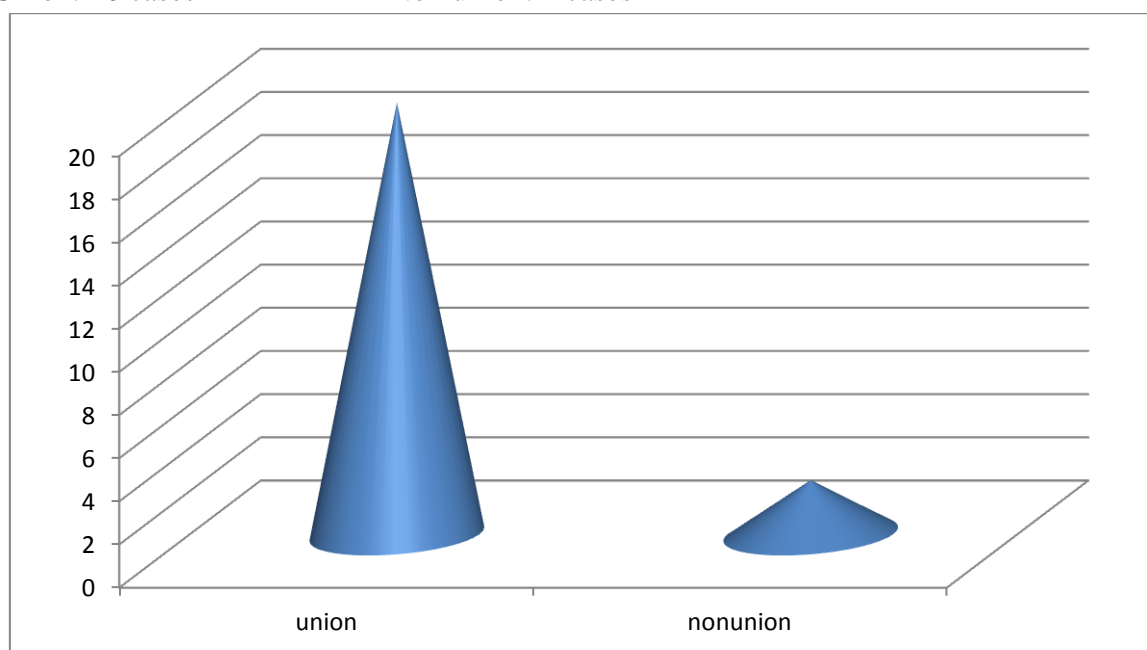
Site	No of Cases
Distal femur	7
Proximal humerus	5
Distal radius	6
Distal tibia	4

**Age Incidence**

Age	No of cases	Percentage
51-60	7	32
61-70	11	50
71-80	4	18

Union: 20 cases

Non union: 2 cases



### Complications

Infection occurred in 1 case, it was treated with culture specific IV antibiotics and non union occurred in 2 cases, bone grafting was done.

### Conclusion

The locking compression plates in the fixation of osteoporotic periarticular fractures has revolutionized the treatment of complicated and failed internal fixation procedures. In regular plate fixation stress will be between screw and bone interface. But in locking compression plate stress will be in the screw and plate interface. Thereby reducing the chance of loosening of screw from the osteoporotic bone. The fixed angle converts shear stress into compressive stress at the screw-bone interface. LCP screws core diameter is bigger than the conventional plating screws, thereby enhancing adequate hold in the osteoporotic bone.

It results in better fixation as chances of implant failure are less. As there is minimal contact of plate and bone surface by implant design there will be minimal disruption of sub-periosteal blood supply to the fracture ends, it helps in good union. The locking between screw and plate prevent further tightening of the screws on bone and so reduction is maintained.

### Limitations

Even though precontoured plates are available for some fracture patterns .A locked plate must be accurately countoured if it is to be used as reduction tool because locked screw will not pull the plate and bone together.

It requires a good learning curve because only experienced surgeon can bend and twist the plate during the procedure.

### References

1. Gardener MJ, Brophy RH, Campbell D, Mahajan A, Wright TM. The mechanical behaviour of locking compression plates compared with dynamic compression plates in a cadaver radius model. *J Orthop Trauma*. 2005 OCT;19(9):597-603.
2. Plecko M, Kraus A. Internal fixation of proximal humerus fractures using the locking compression proximal humeral plate. *Oper Orthop Traumatol*. 2005 Feb;17(1):25-50.
3. Frankhauser F, Boldin C, Schippinger G, Haunschmid C, Szyskowitz R. A new locking plate for unstable fractures of the proximal humerus. *Clin Orthop Relat Res*. 2005 Jan;(430):176-81.



4. Sommer C, Babst R, Mullerr M, Hanson B. Locking compression plate loosening and plate breakage. J Orthop Trauma. 2004 Sep;18(8):571-7.
5. Egol KA, Kubiak EN, Fulkerson E, Kummer Fj, Koval J. Biomechanics of locked compression plate and screws. J Orthop Trauma. 2004 Sep;18(8): 488-93.
6. Gautier , Sommer C. Guidelines for the clinical application of the LCP. Injury 2003.Nov;34 Suppl 2:B63-76.
7. SommerC, Gautier E, Muller M, Helfet DL, Wagner M. First clinical results of the locking compression plate. Injury 2003.Nov;34 Suppl 2:B43-54.
8. Korner J, Lill H, Muller LP, Rommens PM, Schneider E, Linke B.The LCP-concept in the operative treatment of distal humerus fractures-biological, biomechanical and surgical aspects.Injury 2003.Nov;34 Suppl 2:B20-30.
9. AO Manual of Fracture Management. Internal fixators: Concepts and cases Using LCP and LISS. Wagner M, Frigg R, Thieme, Stuttgart, 2006.
10. Egol KA, Kubiask EN, Fulkerson E, et al: Biomechanics of plates and screws. J Orthop Trauma 18(8): 488-493, 2004.